

GODDARD  
VETERINARY  
GROUP

---

**Clare Rusbridge** BVMS DipECVN MRCVS  
European and RCVS and European Specialist In Veterinary Neurology  
**Stone Lion Veterinary Centre**  
41 High Street,  
Wimbledon,  
London, SW19 5AU  
Tel: +44 (0)208 946 4228  
E-mail: [neuro.vet@btinternet.com](mailto:neuro.vet@btinternet.com)

---

Date: 24/04/2009

To whom it may concern:

This is to confirm that on the above date the magnetic resonance images (MRI) of **Celina Colani v.d. Montangards** (Celina)– **VDH-ICC 07/5320** obtained on **4<sup>th</sup> March 2009** were reviewed

**Black and Tan CKCS, female, DOB 23<sup>rd</sup> November 2005**, microchip **528140000209024**  
Owner – **S Haas**

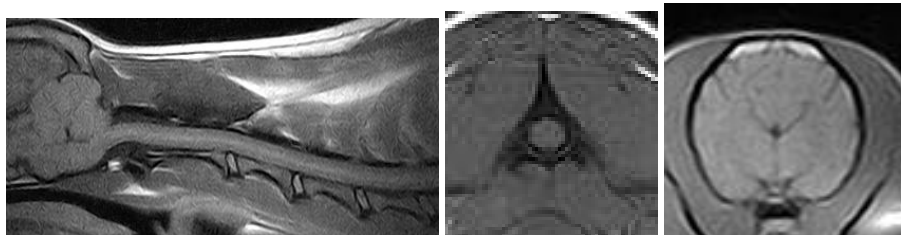
These images reveal:

Chiari malformation of the caudal skull **YES**

Dilatation of the central canal / syringomyelia **NO**

Ventricular dilatation **NO**

**NO** Mucoïd material in tympanic bullae



Using the informal Rusbridge classification the grade of **A** would be attributed to this individual.

Clare Rusbridge BVMS DipECVN MRCVS  
RCVS and European Specialist In Veterinary Neurology

